

# Augmentation Mammoplasty/Mastopexy: Lessons Learned from 107 Aesthetic Cases

Manuel Francisco Castello · Alessandro Silvestri · Fabio Nicoli · Talal Dashti ·  
Sheng Han · Luca Grasseti · Matteo Torresetti · Aurelia Trisliana Perdanasari ·  
Yi Xin Zhang · Giovanni Di Benedetto · Davide Lazzeri



Received: 18 January 2014 / Accepted: 9 July 2014 / Published online: 7 August 2014  
© Springer Science+Business Media New York and International Society of Aesthetic Plastic Surgery 2014

## Abstract

**Background** One-stage augmentation/mastopexy entails the challenge of augmenting breast volume with an implant while resecting excess skin. Although both augmenting and lifting the breast in a one-stage operation is gaining in popularity, its safety and its efficacy are still under debate and merit deeper evaluation.

**Methods** We retrospectively reviewed our experience over a 5-years period with patients who underwent augmentation mammoplasty/mastopexy with the specific objectives of documenting their outcomes and formulating algorithms for safe, simple, and effective operative strategies to manage such patients. Our surgical approach to augmentation/

mastopexy breast ptosis was described step by step. Patient satisfaction with the results was also evaluated.

**Results** One hundred seven patients underwent successful simultaneous augmentation/mastopexy surgery. Sixty-nine underwent primary breast surgery and 38 underwent secondary breast surgery. In 12 cases a periareolar mastopexy scar was used, while in 51 patients a vertical approach was preferred; in 11 and 33 patients a short “T” and an inverted “T” scar mastopexy was necessary, respectively. Few complications were observed, with a very low overall complication rate (14 %) and a reoperation rate of 12.1 % at 14.7 months. Patient satisfaction with the results of this procedure was extremely high.

**Conclusions** Simultaneous augmentation/mastopexy is an effective and versatile way to lift the NAC, tighten the breast skin, increase breast projection, and fill in the upper pole. Our technique of simultaneous breast mastopexy after augmentation through a lower periareolar approach showed excellent correction of pre-existing ptosis, making this method highly reliable because the intraoperative tailor-tacking was customized to the patient, implant size, and projection.

**Level of Evidence IV** This journal requires that authors assign a level of evidence to each article. For a full description of these Evidence-Based Medicine ratings, please refer to the Table of Contents or the online Instructions to Authors [www.springer.com/00266](http://www.springer.com/00266).

---

Manuel Francisco Castello and Alessandro Silvestri contributed equally to this work.

---

M. F. Castello · A. Silvestri · T. Dashti · D. Lazzeri  
Plastic Reconstructive and Aesthetic Surgery, Villa Salaria  
Clinic, Rome, Italy  
e-mail: davidelazzeri@gmail.com

F. Nicoli  
Department of Plastic Reconstructive and Aesthetic Surgery,  
University of Rome, Rome, Italy

S. Han  
Shanghai Tida Medical Aesthetic Hospital, Shanghai, China

L. Grasseti · M. Torresetti · G. Di Benedetto  
Department of Plastic and Reconstructive Surgery, Marche  
Polytechnic University Medical School, University Hospital of  
Ancona, Ancona, Italy

A. Trisliana Perdanasari · Y. X. Zhang (✉)  
Department of Plastic and Reconstructive Surgery, Shanghai  
Ninth People's Hospital, Shanghai JiaoTong University School  
of Medicine, Shanghai, China  
e-mail: zhangyixin6688@hotmail.com

**Keywords** Augmentation mammoplasty · Breast surgery ·  
Mastopexy · Breast implantation · Breast lift · Breast ptosis

## Introduction

Correcting different degrees of breast ptosis with a one-stage augmentation/mastopexy procedure entails the

**Table 1** Ptosis classification<sup>a</sup>

Type	Degree	Description
Grade I	Mild	Nipple position at the level of the inframammary fold
Grade II	Moderate	Nipple position below the inframammary fold but above the lower breast contour
Grade III	Severe	Nipple position below the inframammary fold at the lower contour of the breast
Glandular ptosis	–	Nipple position above the fold but the breast is below the fold

<sup>a</sup> According to Regnault [4]

challenge of augmenting breast volume with a silicone implant while resecting excess skin and concurrently relocating the nipple–areola complex (NAC) and obtaining a full upper pole [1–3].

According to Regnault [4], breast ptosis is classified according to the position of the nipple relative to the inframammary fold when the patient is in the standing position (Table 1). Several authors [3, 5–9] have suggested that performing augmentation and mastopexy in one procedure adds a significant degree of risk and uncertainty to the postoperative results. Other authors [9–11] have claimed that there is an increased degree of ptosis associated with placing breast implants in patients undergoing augmentation/mastopexy, whereas others considered the combined procedure to be safe and effective [12–18]. Nevertheless, the combination of augmentation mammoplasty with mastopexy is gaining in popularity for two main reasons: (1) the limits of subglandular or submuscular implant placement alone to adequately correct sagging skin and (2) a surgical pexy can address only ptosis through the upper relocation of the pre-existing tissues and is not sufficient to restore to the breast the skin tightness, shape, and volume (especially the upper pole fullness) of a young breast. The most obvious advantage of a one-stage procedure of breast augmentation and mastopexy is that it avoids a second operation, thus saving money while reducing the risks related to an additional operation. Moreover, achieving the final outcome with one surgical step avoids disappointing the patient with the result in the intervening period between the two operations. This explains why patients choose an augmentation/mastopexy rather than a two-stage procedure.

Although breast augmentation and lifting are performed in a one-stage operation more and more, the safety and efficacy of the procedure are still under debate and merit more in-depth evaluation. We retrospectively reviewed our experience over a 5-years period with patients who underwent augmentation mammoplasty/mastopexy with the specific objectives of documenting their outcomes and formulating an algorithm for safe, simple, and effective

operative strategies to manage such patients. In addition, we describe our method of augmentation/mastopexy that we have routinely used in our practice as the preferred approach for treating breast ptosis.

## Patients and Methods

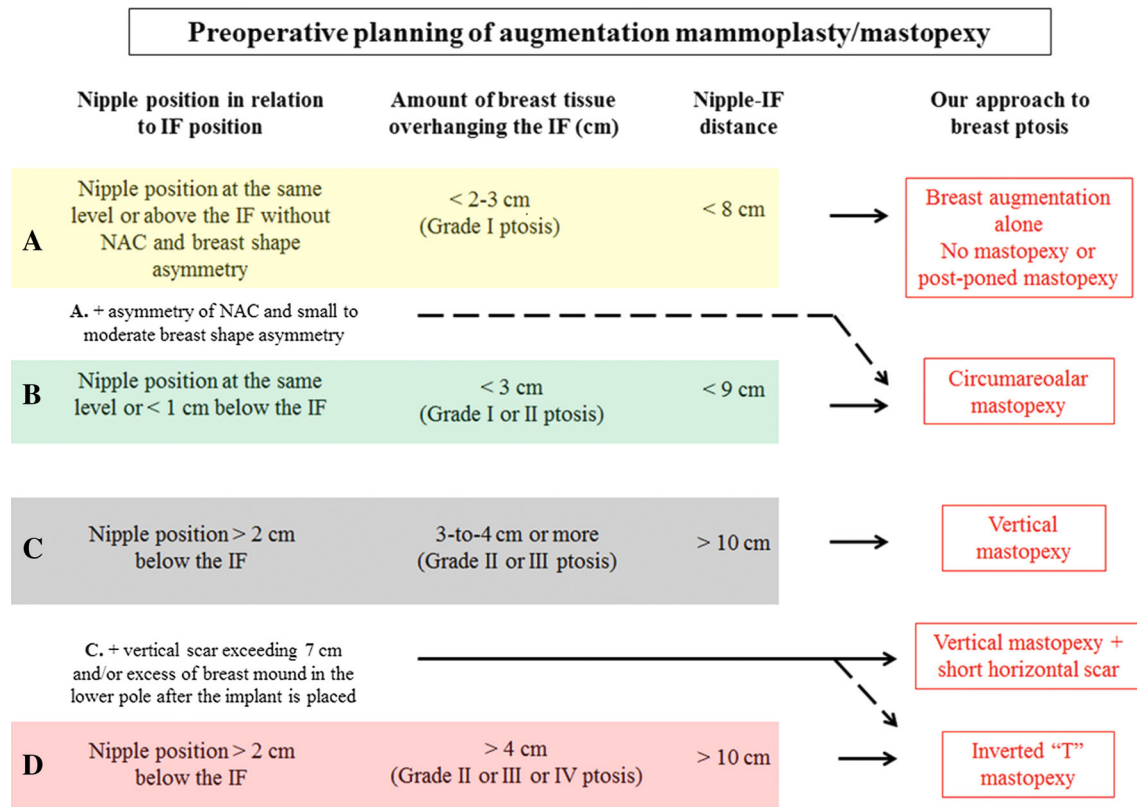
### Patients

Our 5-year-long series (January 2009 to November 2013) of augmentation/mastopexy procedures was investigated retrospectively. Data were collected for 107 patients who underwent simultaneous augmentation and mastopexy. The data included preoperative assessment and anamnestic information, patient demographics, and the surgical approach used. The type of mastopexy used was recorded for each breast as were the type and the location of the implants. Data on additional breast procedures (e.g., implant exchange, location of the pocket exchange) performed concurrently with the scheduled augmentation/mastopexy surgery were collected. Complications related to the augmentation mammoplasty included Baker grade III/IV capsular contracture, implant malposition, seroma and hematoma, implant failure, and infection. Complications related to the mastopexy included partial or extended skin or areola necrosis, hematoma, suture dehiscence, recurrence of breast ptosis, asymmetry of the position and shape of the areola, poor scarring, and breast asymmetry. The request of a patient for implant size exchange after augmentation/mastopexy was included in the list of complications.

### Selection of Patients

During preoperative marking, the type of mastopexy procedure to use was planned, taking into consideration such aspects as the degree of breast ptosis according to Regnault [4] (Table 1), NAC position in relation to the breast mound, how much the breast hung over the inframammary fold, and the amount of vertical excess calculated (distance from the new nipple position to the inframammary fold under stretch), as shown in Fig. 1.

Although preoperative planning of the augmentation/mastopexy procedure is complex and inaccurate because of the high variability of breast ptosis and the presumptive effect of the location of the implant, we followed suggestions that were shared by several authors with experience in this type of surgery [2, 3, 12–18] (Fig. 1). In patients in whom the nipple was virtually at the same level or above the inframammary fold, with less than 2–3 cm of breast hanging over the fold (grade I ptosis) and with a short distance from the nipple to the inframammary fold (usually <8 cm), augmentation alone generally was used to



**Fig. 1** An algorithm for the preoperative planning of augmentation/mastopexy

accomplish the desired result. In these patients, we usually tried to avoid circumareolar mastopexy or at least to postpone it until after the patient had seen the final outcome of the breast implant placement.

Patients who required NAC repositioning or reshaping (grade I or II) with a minimal breast lift were good candidates for circumareolar mastopexy. These patients presented with the nipple at virtually the same level as the inframammary fold or within 1 cm below it, with minimal breast overhang (<3 cm), and the distance between the nipple and the inframammary fold shorter than 9 cm. Further indications for performing circumareolar mastopexy were NAC position and shape asymmetry without breast ptosis.

The vertical-type mastopexy was used when a more severe degree of ptosis was present (grade II or III), including significant breast overhang (3–4 cm or more), nipple located 2 cm or more below the fold, or more than 9 cm between the nipple and the inframammary fold. The removal of a triangle of skin at the lower extremity of the vertical seam (short horizontal scar) was sometimes necessary in these cases.

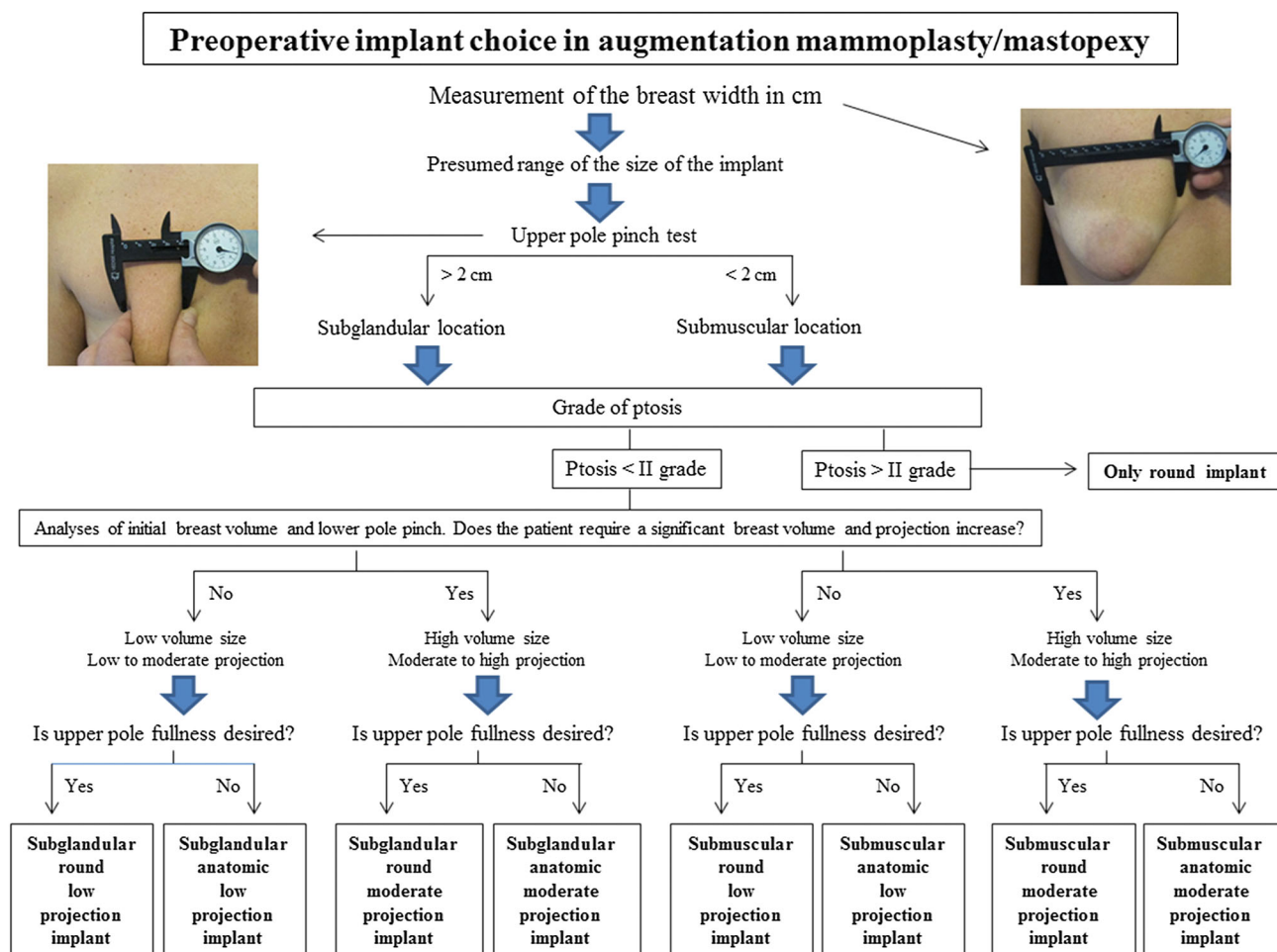
When the vertical excess skin was longer than 10 cm and/or the patient presented with severe ptosis (grade II,

III, or IV) and/or breast tissue hung over the fold by more than 4 cm, an inverted-T approach was the only method indicated to achieve a significant breast lift. Clearly, the greater the vertical excess, the greater the elliptical resection and the length of the resulting inframammary scar. Our algorithm for the management of patients with breast ptosis who were to undergo augmentation/mastopexy is presented in Fig. 1.

The selection of the implant size and projection was based on the anatomical features of the patient's chest wall and breast soft tissue envelope. The width of the breast dictated the size of the implant; the desire of the patient with respect to upper pole fullness and projection was used to choose from round or anatomic implants; and the thickness of the breast tissue determined the placement of the implant, i.e., subglandular or submuscular. Our algorithm for choosing the implant for patients undergoing augmentation/mastopexy is shown in Fig. 2.

## Method

The usual landmarks were drawn on the patient's chest with the patient in an erect position and they included the



**Fig. 2** An algorithm for the preoperative choice of implant in augmentation/mastopexy

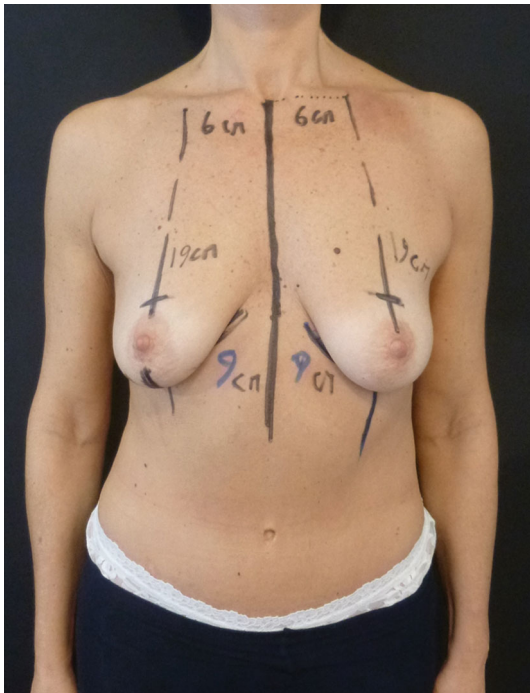
midline of the chest, the breast median, and the existing inframammary fold. The future location of the upper margin of the NAC was marked approximately 18–22 cm from the sternal notch and checked for symmetry with the contralateral one (Fig. 2). The excess skin was grasped with the hand to mimic the postoperative outcome and the boundaries of the skin excision, extending vertically below the areola, were marked. We usually did not maneuver the breast superolaterally and then superomedially to mark the location where the surface of the breast can be pulled to the breast meridian. Although the final design of the cutaneous mastopexy was reconfirmed by tailor-tacking in the intra-operative period after insertion of the breast implant, pre-operative evaluation was critical for patient counselling and surgical planning.

With the patient under general anesthesia and in the supine position, the areolae were incised with a 4.5 cm-diameter areola cutter. Through a semicircular approach in the new inferior margin of the areola, either a subglandular or a subpectoral pocket was created using a traditional

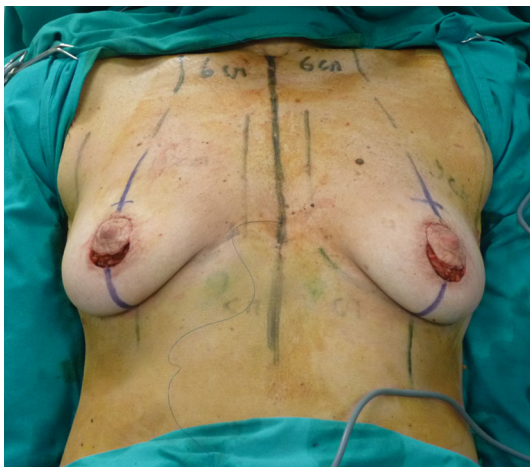method (Fig. 3). Augmentation of the breast was performed with placement of anatomic or round textured silicone implants into the pocket after careful hemostasis and insertion of a suction drain. When the implant was located in the subpectoral pocket, the abdominocostal pectoralis attachments were sectioned and a full-thickness incision of the pectoralis muscle was made on a vertical line on the nipple projection for 4–5 cm, according to Pelle-Ceravolo et al. [19]. These steps were done to minimize postoperative animation deformities, enhance the projection of the nipple, and decrease the upward pushing of the implant during contraction of the pectoralis muscle. The deep glandular layer was sutured with resorbable stitches to isolate and secure/preserve the pocket containing the implant.

Once the implant was placed, the patient was lifted into a sitting position (Fig. 4). Tailor-tacking was performed, starting at the cross at the upper extremity of the planned vertical scar and extending inferiorly toward the fold, thereby creating the desired breast shape and lift. The



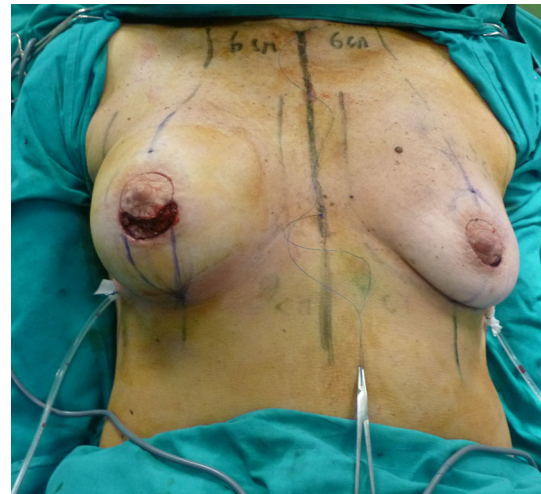

**Fig. 3** The patient was marked, including the midline of the chest, the breast median, and the existing inframammary fold. The future location of the upper margin of the NAC was marked about 18–22 cm to the sternal notch

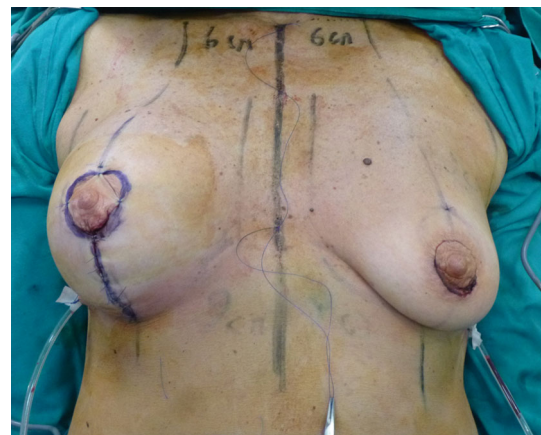

**Fig. 4** A subglandular pocket was created through a semicircular approach in the new inferior margin of the areola. Some deep resorbable stitches were used to close the pocket

nipple position was determined intraoperatively without a mosque-dome pattern. Therefore, the vertical breast closure and the new nipple position were tailor-tacked using a nylon suture to determine the exact amount of excess skin that should be removed in the area between the nipple and the inframammary fold (Figs. 5 and 6). At this time, the

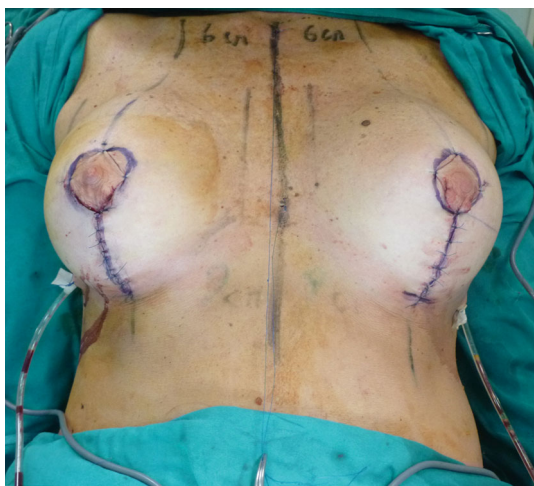

**Fig. 5** A 240LO round Silimed implant was placed in the right breast

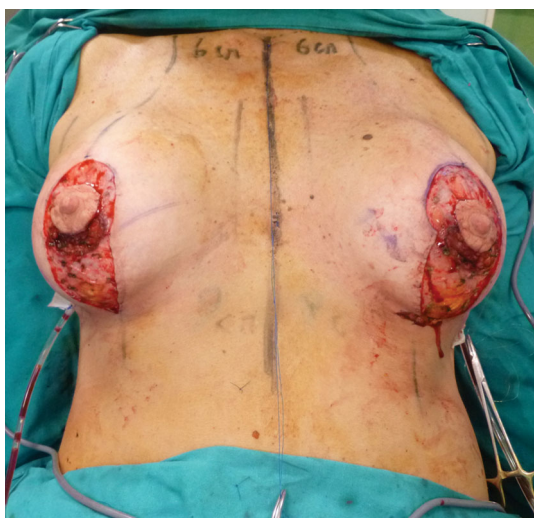

**Fig. 6** The skin was tailor-tacked using a nylon suture to determine the exact amount of excess skin between the nipple and the inframammary fold that should be removed. The procedure started at the cross at the upper extremity of the planned vertical scar and extended inferiorly toward the fold, creating the desired breast shape and lift

need for a short or a long transverse seam became evident (vertical scar exceeding 7 cm and/or excess of breast mound in lower pole), and the same procedure of tailor-tacking was applied to the horizontal excess. After the necessary tension was checked, the stitches were removed and methylene blue was used to mark the definitive vertical incision (Fig. 7). The periareolar excess skin was always deepithelialized to avoid jeopardizing the vascular supply of the NAC, whereas the trimming of the vertical and excess inframammary transverse skin included a quantity of breast tissue when necessary, being careful to avoid any excessive thinning of the tissues overlying the implant. In



**Fig. 7** Once both implants were placed and the skin envelopes tailored, the breasts were checked for symmetry

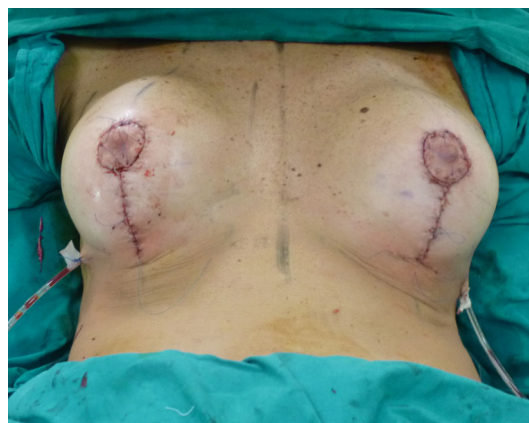

**Fig. 8** After the necessary tension was checked, the stitches were removed and *methylene blue* was used to mark the definitive vertical incision. Finally, the skin included in the marking was deepithelialized

this way, all of the excess skin present after placement of the implant was safely removed.

The lower edge of the neoareola was marked to keep it within 6.5–7 cm from the inframammary fold. The NAC was repositioned and additional sagging periareolar skin was eventually removed (Figs. 8, 9).

Large periareolar defects resulting from deepithelialization, independent of the type of mastopexy, were managed with the interlocking purse-string suture (achromic 3/0 Nylon), following Hammond et al. [20]. This avoided excessive widening and distortion of the shape of the areola by balancing the existing contrast between the NAC



**Fig. 9** Final appearance

centripetal and outer breast tegument centrifugal forces [21]. As reported by Hammond [20] the cinching effect of the periareolar nonresorbable suture pulled the deepithelialized dermal shelf slightly under the peripheral edge of the incised areola, thus providing a mild vest-over-pants-type layer of protection for the suture. The periareolar suture was completed with some resorbable stitches as needed and an external intradermal 3/0 prolene suture that was removed after 3 weeks.

#### Questionnaire

Patients were seen on postoperative days 3, 7, 14, and 21 and at 1 month, and then at 3-, 6-, and 12-month intervals. As in our previous investigation [22], we used a study-specific questionnaire to assess patient satisfaction with the aesthetic outcome after breast augmentation revision. They were asked to complete the questionnaire before the last examination (12 months after surgery) to prevent the results from the examination from influencing their answers. The questionnaire included the following:

- On a scale of 0–5 (0, disappointed; 5, very satisfied), how satisfied are you with the treatment and the overall aesthetic outcome?
- On a scale of 0–5, how satisfied are you with the final size of your breast?
- On a scale of 0–5, how satisfied are you with the final shape of your breast?
- On a scale of 0–5, how satisfied are you with the final symmetry and NAC location of your breast?
- Are the required outcomes of the simultaneous augmentation/mastopexy still maintained?
- What is your impression about the outcomes? Have your expectations been fulfilled?
- Would you recommend this treatment to other patients?

**Table 2** Patient characteristics and data for our 107 simultaneous augmentation/mastopexies

Age	
Range	26–69
Average	42 ± 5.6
BMI	
Average	23.7 ± 3.7
≤18	1.80 %
18–24.9	63.50 %
25–29.9	29.90 %
≥30	4.60 %
Preoperative breast size <sup>a</sup>	
A	13.1 %
B	54.3 %
C	25.2 %
D	7.40 %
Smokers (≥10 cigarettes/day)	19 patients (17.7 %)
Location of implants	
Subglandular	70
Subpectoral	37
Implant size (cc)	
Average	240 ± 30
≤200	0.90 %
200–300	62.60 %
300–400	31.80 %
≥400	4.70 %
Type of mastopexy	
Periareolar	12
Vertical	51
Short “T”	11
Inverted “T”	33
Type of implant	
Anatomic	32
Round	75
Type of operation	
Primary	69
Secondary	38
Outcome (follow-up months)	
Range	3–29
Average	14.7
Complications	Resolutions
Implant-related	
Capsular contracture ( <i>n</i> = 2)	Breast implant exchange
Breast asymmetry ( <i>n</i> = 1) <sup>b</sup>	Breast lipofilling
Hematoma ( <i>n</i> = 1)	Surgical evacuation
Seroma ( <i>n</i> = 1)	Outpatient multiple aspirations
Unsatisfactory size ( <i>n</i> = 3) <sup>b</sup>	Implant size exchange
Mastopexy-related	
Unpleasant scar ( <i>n</i> = 1)	Outpatient corticosteroid injection
Areola asymmetry ( <i>n</i> = 2)	Outpatient surgical symmetrization

**Table 2** continued

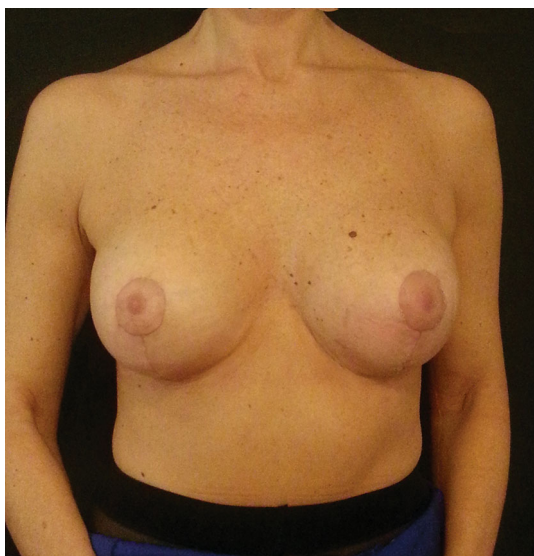Persistent breast ptosis ( <i>n</i> = 4) <sup>b</sup>	Revision cutaneous mastopexy alone
Overall complication rate was 14 % (11.6 % for primary cases and 18.4 % for secondary cases) and overall reoperation rate was 12.1 % (7.2 % for primary cases and 21.1 % for secondary cases)	
<sup>a</sup> Only for primary augmentation/mastopexy	
<sup>b</sup> Three of the patients who developed complications (1 breast asymmetry, 1 unsatisfactory size, and 1 persistent breast ptosis) were heavy smokers but the type of complication was not related to the consequences produced by smoking on tissue and vascularity	

## Results

One hundred seven patients underwent successful augmentation/mastopexy surgery and were followed up an average of 14.7 months. The average age was 42 years (range = 26–69 years). Of these patients, 69 underwent primary breast surgery and 38 secondary breast surgery (Table 2). Of the 38 secondary cases, 7 were unsatisfactory previous breast augmentations performed less than 5 years before. The patients considered the surgery a failure because of asymmetry (*n* = 3) or inadequate lifting of the sagging breast (*n* = 2) or the wrong size implant was used (*n* = 2). Fifteen of the 38 secondary cases were previous breast augmentations performed more than 5 years before (range = 6–11 years, mean = 9.2 years), including 8 patients who complained about the drop of the breast implants, 3 patients with the diagnosis of implant rupture, and 4 patients who wanted to reduce the size of the breast. These 22 secondary cases could be not considered a “staged” augmentation and mastopexy procedure because the first implant was always exchanged for a new one that could be different in size, shape, and location. Furthermore, in the interval between the primary breast surgery and the secondary augmentation/mastopexy, the patient’s skin and soft tissue quality may have dramatically changed and ptosis may have worsened. Five patients had previous mastopexy alone and required secondary surgery because of unsatisfactory breast volume and unaesthetic upper pole hollowness, and 11 patients had previous augmentation/mastopexy in which the wrong size implant was used and/or there was asymmetry of volume (*n* = 6) and inadequate breast lifting (*n* = 5).

Using the approach described in the Methods section, we performed augmentation using textured silicone anatomic implants in 32 cases and round implants in 75 patients (70 %) (Table 2), with a mean volume of 240 ± 30 ml. We used the subglandular location for the device in 70 patients, and subpectoral placement in the remaining 37 cases. In 12 cases a periareolar mastopexy scar was used, while in 51 patients a vertical approach was





**Fig. 10** The patient in Figs. 1–7 at the 6-month follow-up

preferred. In 11 patients a short horizontal scar was combined with the vertical approach and in 33 patients an inverted-T scar mastopexy was necessary.

Few complications were observed for a notably low overall complication rate of 14 % (11.6 % for primary cases and 18.4 % for secondary cases) (Table 2) and a reoperation rate at 14.7 months of 12.1 %. Eight complications were related to implant location. Two patients developed unilateral and bilateral capsular contracture, respectively, and were treated with bilateral breast implant and plane exchange (from subglandular to submuscular, and with a new precapsular subpectoral placement [22]). One patient complained of breast asymmetry and required lipofilling. One patient developed a hematoma that required surgical exploration and evacuation the day after the procedure. One patient developed a seroma that needed aspiration several times during follow-up in the outpatient clinic. Three patients desired implant size exchange. Seven complications were related to the mastopexy procedure. One patient was unsatisfied with the scars and two patients were unsatisfied with areolar asymmetry. All three cases were corrected in the outpatient facility: the first patient with corticosteroid injection and the other two with surgical symmetrization under local anesthesia. Four patients complained of persistent breast ptosis and underwent reoperation with cutaneous mastopexy alone. Some examples of significant cases are shown in Figs. 10–14.

A total of 98 patients (91.5 % of all cases) responded to the questionnaire; the remaining 9 patients were contacted by telephone and responded to the survey. The patients with complications were asked to complete the survey after the complications were resolved. Overall, all of the patients

were satisfied after their augmentation/mastopexy procedure. Table 3 summarizes the results of the questionnaire completed by the patients.

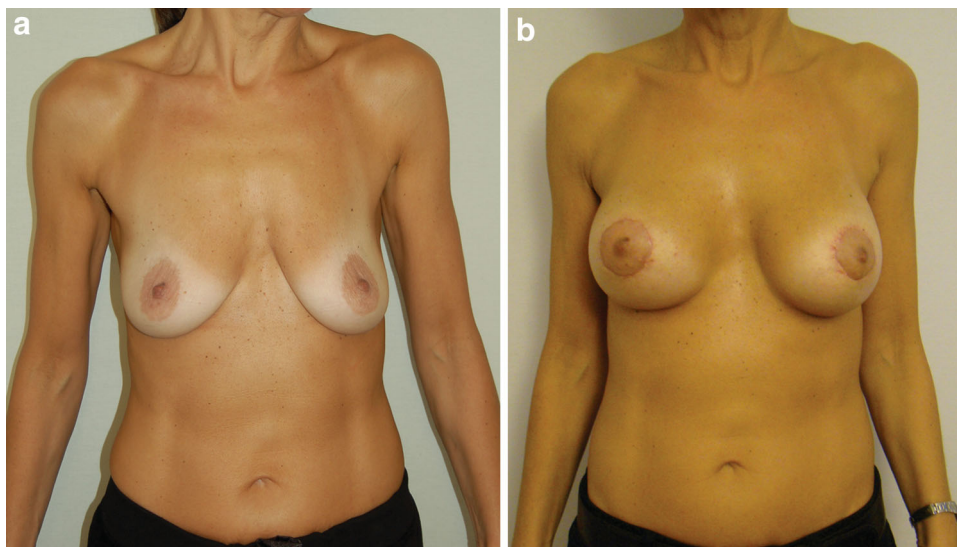
## Discussion

Since it was first described in the 1960s by Gonzales-Ulloa [23] and Regnault [24], one-stage augmentation/mastopexy has experienced alternating periods of popularity, failure, and resurgence of interest [1–3, 7–18, 25, 26]. The criticism is logical because the purposes of the two procedures are in contrast: augmentation with an implant has the goal of filling the sagging skin and stretching it, while mastopexy with a vertical or inverted-T scar has the purpose of lifting the skin and the NAC by tightening the skin envelope. The resulting complication rate of the combined procedures exceeds the sum of the complication rates of the procedures done separately [25].

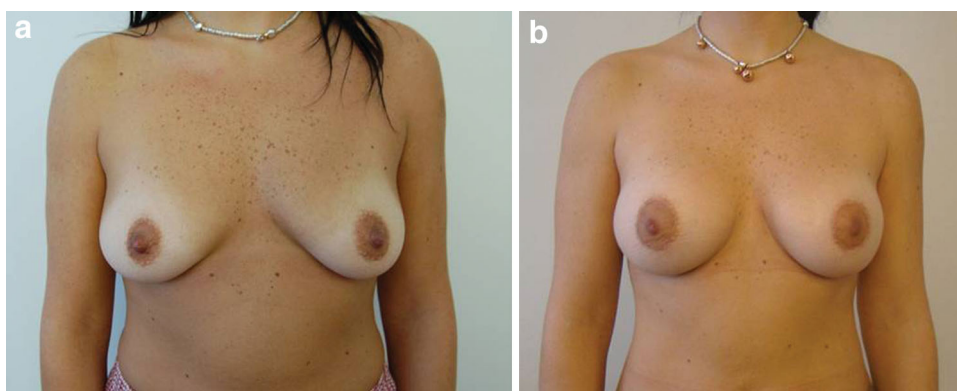
The safety and efficacy of combining augmenting and lifting the breast into a single-stage operation remain under debate. Several retrospective investigations and one prospective study highlighted the advantages of the combined technique to address breast ptosis and volume increase [12–18]. Conversely, several authors are still skeptical and have advocated a staged approach to avoid the risks related to the simultaneous use of both methods, including difficulty in perfectly positioning the nipple, poor scarring, poor NAC-implant alignment, NAC malposition and asymmetry, and implant extrusion, all of which lead to a high revision rate with this operation [3, 5–9]. The lack of a detailed description in previous investigations of the peri-operative surgical planning and decision-making and their impact on the final result explains why there is no global consensus on augmentation/mastopexies in the literature [1–3, 7–18]. Certain general guidelines may be provided, as presented in the Patients and Method section and in Figs. 1 and 2. Even if it is possible to have an algorithm that could guide the surgeon toward the safest and most effective method of augmentation/mastopexy for every case, the combination of individual patient's factors and the surgeon's experience should be always taken into consideration (Figs. 1 and 2). In our experience patients preferred a single-stage lift with augmentation. During the outpatient visit with us, the patients who were referred to us for correction of breast ptosis were fully informed about the pros and cons of staged and simultaneous augmentation/mastopexy. Although the decision is supposed to be the patient's own choice and not to be influenced by the surgeon, three main factors usually swayed the patients to choose a simultaneous procedure. First, patients appreciated the possibility of correcting all the complaints at one time even after they were fully informed about the risks



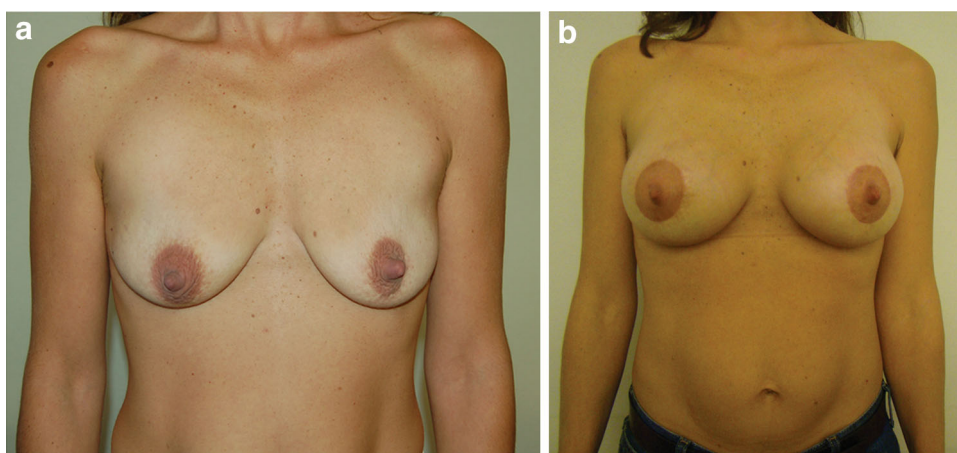
**Fig. 11** A 47-year-old patient who underwent augmentation mammoplasty with the placement of 300 M + Mentor round subglandular silicone implants combined with periareolar mastopexy. Results 8 months after surgery



**Fig. 12** A 35-year-old patient underwent simultaneous periareolar augmentation/mastopexy with 240LO Silimed round implants. Results 13 months after surgery



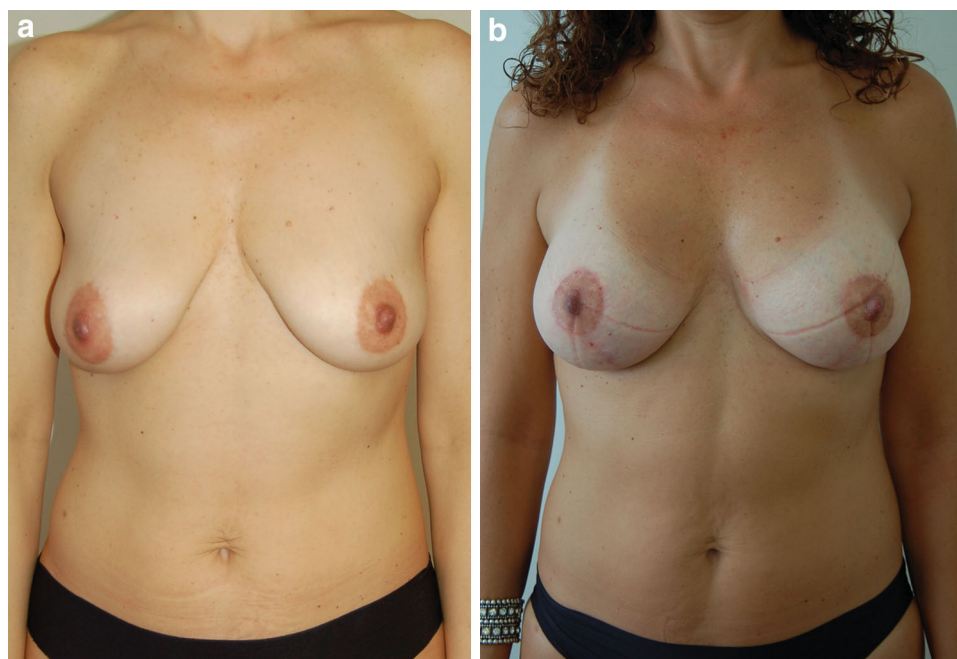
**Fig. 13** A 42-year-old patient underwent vertical augmentation/mastopexy with 330HP Mentor round implants. Results 15 months after surgery



and complications of the one-stage procedure. Patients undergoing cosmetic breast surgery usually seek a fast resolution of their deformities and can achieve the final outcome in one surgical step, thus avoiding the disappointment that can occur in the period between the two operations of a staged approach. Second, despite arguments

on both sides, the long experience of the senior authors with the simultaneous approach indirectly influenced the choice of the patients toward a simultaneous procedure during the consultation. Third, almost one third of the patients came to our outpatient facility because they were already aware of the outcomes of simultaneous

**Fig. 14** A 45-year-old patient underwent vertical augmentation/mastopexy with 240MD silimed anatomical implants. Results 10 months after surgery



**Table 3** Patient self-assessment<sup>a</sup> of aesthetic outcomes by those who underwent simultaneous augmentation/mastopexy with our method

Patient's self assessment	Mean score (SD)
Size of breast	4.23 ( $\pm$ 0.3)
Shape of breast	4.38 ( $\pm$ 0.6)
Breast symmetry	4.06 ( $\pm$ 0.4)
NAC location	3.96 ( $\pm$ 0.7)
Overall aesthetic outcome	4.31 ( $\pm$ 0.38)

A 6-grade scale was used in each category: 5 = very satisfied, 4 = good, 3 = acceptable, 2 = bad, 1 = very bad, and 0 = failed

<sup>a</sup> According to Castello et al. [22]

augmentation/mastopexy performed by us on their friends, relatives, or colleagues.

Previous investigations described the simultaneous approach as safe and effective for patients. Spear et al. [7] had 8.7 and 16.6 % revision rates for primary and secondary augmentation/mastopexy procedures, respectively, highlighting the heightened level of preparation, planning, and caution that was used, particularly with regard to siting the nipple, preserving blood supply, and achieving a secure and appropriately snug closure of the breast. In his significant 10-years prospective study, Swanson [18] reported a complication rate of 36.3 % for augmentation/mastopexy and 33.3 % for mastopexy alone, which were double that for breast augmentation of 17.6 %, and a revision rate after augmentation/mastopexy of 20.5 % compared with a rate of 24.6 % after mastopexy and 10.7 % after breast augmentation. For all his patients Swanson performed submuscular implant placement and vertical parenchymal

resection with a medial pedicle and intraoperative determination of nipple positioning. Swanson concluded that the combined procedure of augmentation/mastopexy offered technical advantages and was safe as single-stage surgery, and it yielded complication and revision rates that were less than the calculated cumulative rates for the procedures performed separately. Colabrace et al. [2] reported an overall complication rate of 22.9 % for simultaneous augmentation/mastopexy procedures, with an overall reoperation rate of 23.2 % (primary cases, 20.0 %; secondary cases, 30.9 %). The authors concluded that the revision rate of the combined procedure was not more than the total of the revision rates of the two procedures done separately. They advocated that appropriate patient selection and a carefully planned operative approach were the mainstays to performing the one-stage procedure safely and with acceptable complication and reoperation rates [2].

In our series we had an overall complication rate of 14 %, half of which was related to the augmentation procedure and the other half to the mastopexy procedure. Our reoperation rates (including primary and secondary augmentation/mastopexy) were similar to those described retrospectively or prospectively in the literature [1–3, 7–18, 26–28]. In addition, our implant-related reoperation rate of 7.4 % for the simultaneous procedure did not appear to be greater than the reoperation rate reported for breast augmentation. As shown in Table 2, the overall complication and reoperation rates of secondary surgery are much higher than primary augmentation/mastopexy because revision breast surgery is more challenging than primary breast surgery for several reasons. The surgeon has to deal with

scarred and stretched tissues caused by previous implants and/or mastopexy scars, making it more difficult to predict a good result. In addition, previous poor implant selection and improper plane location of the prosthesis further increase the difficulty for achieving a successful outcome with secondary surgery. This should not limit the surgeon in selecting the patient but the patient should be fully informed about the limits of secondary surgery.

In our series, subglandular placement of the implant was preferred when at least 2 cm of tissue was present when the upper breast pole was pinched. We did not observe any superiority of subglandular versus submuscular placement of the implant with respect to a natural-looking outcome; however, we believe that the most important factor in retaining the natural appearance of the breast over the long term is tissue coverage. Therefore, we suggest that the implant be placed in a subglandular pocket when the thickness of the upper pole is adequate because there is a small advantage of subglandular over subpectoral placement in this situation. With subpectoral placement, some minor animation deformities can occur when the muscle is strongly contracted. The direct apposition of the implant against the lax breast envelope helps fill out a droopy envelope. Round implants were used in two-thirds of our cases because of the patients' desire to have upper breast pole fullness. We have a lot of experience with polyurethane foam-covered implants and it is our opinion that they should not be used in augmentation/mastopexy [29]. They have become widely popular for augmentation and secondary revision breast surgery because of a reduced risk of capsular contracture with them. This is due to the ability of the implant's external 1–2 mm-thick polyurethane layer to produce an inflammatory reaction which impedes the formation of a fibrous capsule around the implant. However, the highly adherent textured surface of the polyurethane layer grasps and fixes to the surrounding tissues resulting in a long-term unpleasant and unnatural outcome.

Our technique preserved the integrity and the entire soft tissue thickness of the breast's lower pole. The breast parenchyma was violated only in the lower periareolar area through which the pocket was created. Although it was a single-stage technique, the ability to separate the augmentation procedure from the mastopexy procedure allowed the implant to be protected from the external environment. With our method, the location of the implants was safer and the risk of rippling (i.e., lower visibility and palpation of the implant's edges) in the lower pole was considerably reduced. Only cutaneous mastopexy allowed the preservation of the integrity of the glands and subcutaneous layers of the lower pole, thereby increasing the coverage of the implant. The implants did not need flaps or a surgical incision to be supported. In contrast, several authors [26, 27] suggested the use of an inferior pedicle to

protect and support the implant and prevent it from sliding down the mammary fold and emptying the bosom. These authors [24] also observed alleviation in patient discomfort on palpation of the implants in the lower pole. We believe that the inferior pedicle of an inverted-T procedure is prone to compression caused by pressure from the implant, thereby reducing the margin of safety and leading to predictable and sometimes disastrous consequences [8, 9, 17, 18]. Gomes [28] described a mastopexy technique with subglandular breast augmentation that used a superior pedicle flap surrounding the implant. They experienced a 7 % recurrence rate of ptosis, 17 % of vertical seam dehiscence, and 9 % of unsatisfying scarring [27].

Although a number of researchers still advocate that an adequate lower-pole parenchymal resection is needed to avoid the occurrence of a “mastopexy-wrecking” bulge with a vertical mastopexy, we agree with Spear et al. [7] that this practice should definitely be avoided when an implant is included because its soft tissue coverage will be compromised, thus increasing the risk of implant-related complications. We did not use a flap to cover the lower breast implant, nor did we resect the lower-pole parenchyma. This may explain why we did not have any breast or implant infection, extrusion, or exposure. The preservation of the integrity of the lower-pole parenchyma prevented any increase of suture dehiscence, occurrence of implant compromise, or implant palpability, enhancing the patients' overall satisfaction.

## Conclusions

Simultaneous augmentation/mastopexy is an effective and versatile way to lift the NAC, tighten the skin, increase breast projection, and fill the upper pole more predictably than with mastopexy alone. With proper patient selection and appropriate preoperative planning, the single-stage approach can be performed safely with low complication and reoperation rates.

Our technique of performing simultaneous breast mastopexy after augmentation through a lower periareolar approach enabled safer location of the implants with good correction of pre-existing ptosis. The conservative skin removal after implantation makes this technique highly versatile and reliable because the intraoperative tailoring can be customized to patient, the implant size, and the projection. The risk of lower-pole rippling is thus avoided. A very low overall complication rate and extremely high patient satisfaction have been observed with this procedure.

**Conflicts of interest** The authors have no financial interest to declare with respect to the content of this article.



## References

- Hidalgo DA, Spector JA (2013) Mastopexy. *Plast Reconstr Surg* 132:642e–656e
- Calobrace MB, Herdt DR, Cothron KJ (2013) Simultaneous augmentation/mastopexy: a retrospective 5-year review of 332 consecutive cases. *Plast Reconstr Surg* 131:145–156
- Spear SL, Boehmler JH 4th, Clemens MW (2006) Augmentation/mastopexy: a 3-year review of a single surgeon's practice. *Plast Reconstr Surg* 118:136S–147S
- Regnault P (1976) Breast ptosis: Definition and treatment. *Clin Plast Surg* 3:193–203
- Hoffman S (2004) Some thoughts on augmentation/mastopexy and medical malpractice. *Plast Reconstr Surg* 113:1892–1893
- Nahai F, Fisher J, Maxwell PG, Mills DC II (2007) Augmentation mastopexy: To stage or not. *Aesthet Surg J* 27:297–305
- Spear SL, Boehmler JH 4th, Clemens MW (2006) Augmentation/mastopexy: a 3-year review of a single surgeon's practice. *Plast Reconstr Surg* 118(7 Suppl):136S–147S
- Spear SL, Giese SY (2000) Simultaneous breast augmentation and mastopexy. *Aesthet Surg J* 20:155–163
- Spear SL, Pelletiere CV, Menon N (2004) One-stage augmentation combined with mastopexy: Aesthetic results and patient satisfaction. *Aesthetic Plast Surg* 28:259–267
- Pitanguy I, Carreira S, Mazzarone F, Fróes LB, Cló TT (1991) Mastopexia associada à inclusão de prótese. *Rev Bras Cir* 81(2):101–111
- Carramaschi FR, Tanaka MP (2003) Mastopexia associada à inclusão de prótese mamária. *Rev Soc Bras Cir Plást* 18(1):25–36
- Gallent IM, Pons MR, Drever M (2003) Vertical scar mastopexy with an implant. *Aesthetic Plast Surg* 27:406–410
- Karnes J, Morrison W, Salisbury M, Schaeferle M, Beckham P, Ersek RA (2000) Simultaneous breast augmentation and lift. *Aesthetic Plast Surg* 24:148–154
- Stevens WG, Freeman EM, Stoker DA, Quardt SM, Cohen R, Hirsch EM (2007) One-stage mastopexy with breast augmentation: A review of 321 patients. *Plast Reconstr Surg* 120:1674–1679
- Stevens WG, Stoker DA, Freeman ME, Quardt SM, Hirsch EM, Cohen R (2006) Is one-stage breast augmentation with mastopexy safe and effective? A review of 186 primary cases. *Aesthet Surg J* 26:674–681
- Tessone A, Millet E, Weissman O et al (2011) Evading a surgical pitfall: Mastopexy-augmentation made simple. *Aesthetic Plast Surg* 35:1073–1078
- Persoff MM (2003) Mastopexy with expansion-augmentation. *Aesthet Surg J* 23:34–39
- Swanson E (2013) Prospective comparative clinical evaluation of 784 consecutive cases of breast augmentation and vertical mammoplasty, performed individually and in combination. *Plast Reconstr Surg* 132(1):30e–45e
- Pelle-Ceravolo M, Del Vescovo A, Bertozzi E, Molinari P (2004) A technique to decrease breast shape deformity during muscle contraction in submuscular augmentation mammoplasty. *Aesthetic Plast Surg* 28(5):288–294
- Hammond DC, Khuthaila DK, Kim J (2007) The interlocking Gore-Tex suture for control of areolar diameter and shape. *Plast Reconstr Surg* 119(3):804–809
- Righi B, Robotti E (2011) Successfully exploiting two opposing forces: a rational explanation for the “interlocking suture”. *Aesthetic Plast Surg* 35(2):177–183
- Castello MF, Lazzeri D, Silvestri A, Agostini T, Pascone C, Marcelli C, Gigliotti D, D'Aniello C, Gasparotti M (2011) Maximizing the use of precapsular space and the choice of implant type in breast augmentation mammoplasty revisions: review of 49 consecutive procedures and patient satisfaction assessment. *Aesthetic Plast Surg* 35(5):828–838
- Gonzalez-Ulloa M (1960) Correction of hypotrophy of the breast by means of exogenous material. *Plast Reconstr Surg* 25(1):15–40
- Regnault P (1966) The hypoplastic and ptotic breast: A combined operation with prosthetic augmentation. *Plast Reconstr Surg* 37:31–37
- Spear SL, Dayan JH, Clemens MW (2009) Augmentation mastopexy. *Clin Plast Surg* 36:105–115
- Sánchez J, Carvalho AC, Erazo P (2008) Mastopexia com prótese: técnica em “D” espelhado. *Rev Bras Cir Plást* 23(3):200–206
- Mansur JR, Bozola AR (2009) Mastopexia e aumento das mamas com proteção e suporte inferior da prótese com retalho de pedículo inferior. *Rev Bras Cir Plást* 24(3):304–309
- Gomes RS (2008) Mastopexia com retalho de pedículo superior e implante de silicone. *Rev Bras Cir Plást* 23(4):241–247
- Castello MF, Han S, Silvestri A, Grassetti L, Torresetti M, Zhang YX, Perdanasari AT, Marcelli C, Gigliotti D, Lazzeri D (2014) A simple method to inset and position polyurethane-covered breast implants. *Aesthetic Plast Surg* 38(2):365–368